

XIX. *Account of an Ossification of the Thoracic Duct*
 By Richard Browne Cheston, *Surgeon to the Infirmary*
at Gloucester; communicated by Mr. Henry Watfon,
Surgeon to the Westminster Hospital.

Read April 20, 1780.

JAMES JONES, twenty-two years of age, was admitted into the Gloucester Infirmary, June the 5th, 1779, for very troublesome pains in his back and hip, which, from every circumstance of his description, were supposed rheumatic.

Upon a particular examination a few days afterwards, the right hip was observed to be fuller than it should be; but the thigh seemed very little altered from its natural state. A blister was applied over the joint, and the usual anti-rheumatic remedies were prescribed by the physician under whose care he was admitted. In about a fortnight he complained of a violent pain in his knee, for which another blister was ordered to the head of the fibula. During this time he could move about the ward

VOL. LXX.

X x

by

by the assistance of a stick, but soon after not without crutches.

His thigh now increased in bulk, and became œdematous; for which reason another blister was applied about the middle of it, and his knee getting into a contracted state, a volatile liniment was rubbed on that part. As he now could not move about, even with the assistance of crutches, he took to his bed altogether.

From this time the enlargement of his thigh advanced very fast, and his knee became contracted in proportion; so that the thigh had got into the same kind of relaxed position the limb is frequently placed in when the bone is fractured.

Soon afterwards he began to find some difficulty in the discharge of his urine, which by degrees increased so much, that the medicines prescribed for his relief in this particular, not having the desired effect, and his belly appearing to be distended from this cause, a catheter was attempted to be introduced, but it could not be made to pass the neck of the bladder: a bougie, however, entered the bladder with ease, and some water came off upon withdrawing it.

From this period, by means of very great exertions of the abdominal muscles, and by occasional pressure externally, he used to discharge his urine; but it came away

in small quantities only at a time, and seemed to empty the bladder but very little; for a tumor, which for many days had been perceptible on the left side, and which evidently contained a fluid, afforded the usual feel of a distended bladder.

He now suffered very violent pains all over the abdomen, but particularly about the region of the pubis, so that he could not bear the pressure usually made for some time past to force off his urine; and, as the catheter could not enter the bladder, and the introduction of the bougie was of very little service, his urine now began to dribble away involuntarily.

His fever, at intervals, was very considerable, his strength failed him very fast, and he received no benefit from any medicines but opiates. In this most deplorable condition he languished till the beginning of October, when the violence of his pains began to remit, and he gradually drooped into a state of insensibility till the tenth of October, when he died.

DISSECTION.

The integuments of the abdomen felt harsh and dry, like a piece of parchment. The veins were much enlarged, and their branches could be traced all over its

surface in a very distinct manner. On the left side there still remained an evident fullness, which pushed the integuments forwards to the size of two fists, and which contained a fluid in considerable quantity.

The thigh still continued in the same position and œdematous state before described, so that from those circumstances, and the distension of the abdomen, nothing particular could be observed externally, at the lower part of the abdomen, on the right side more than on the left.

Upon examining the cavity the intestines presented themselves nearly in their natural situation: their appearance was found, but in general they were much inflated. The tumor on the left side proved to be the bladder distended with urine, slightly adhering to the peritoneum; and this, together with the colon passing on to its termination in the rectum, filled up the iliac region on that side, while the right side, and indeed more than half the pelvis, was fully occupied by a confused irregular mass, seemingly formed of scirrhus cartilage, bone, and stone.

As a large cartilaginous substance ^(a) arising from this mass seemed to cover the bodies of the vertebræ, I removed the intestines, and pursuing this singular appear-

(a) This substance, when first taken out of the body, appeared cartilaginous; but when dried was perfect bone.

ance, traced it upwards in the course of the spine, and of the large blood vessels, to its termination somewhat above the kidneys.

Upon laying bare the sternum and ribs, to inspect the cavity of the thorax, the cartilages presented themselves in the whitest state I ever saw, approaching nearly to the colour of writing paper, still retaining their natural firmness and texture.

The lungs were in a full state of distension, and studded in many parts with the same kind of cartilaginous substance which appeared so plentifully in the lower cavity.

Suspecting that the arterial system might, in some measure, be affected by this prevailing disease, I separated the heart from the lungs, for the purpose of examining its larger system of vessels, and, dividing the aorta just below its curvature, found, upon examination, the heart very flaccid, empty, and of a much smaller size than usual in adults of the age of this patient, but found in every respect.

The semi-lunar and mitral valves were not at all diseased, nor was there the smallest deviation in any part of the aorta from the most healthy state, though it was entirely surrounded by this singular substance from the
passing

passing off of the coeliac artery to where it bifurcates into the two iliacs.

On raising the aorta from the spine, after I had divided it at its curvature, I found a singular firmness on its right side, like a piece of hard pack-thread, and exactly in the situation of the thoracic duct. I continued my dissection therefore with great caution, and at such an extent as to take in the vena azygos, and afterwards found upon clearing it at my leisure, that it really was the thoracic duct, intirely plugged up with officic matter, from immediately above the receptaculum chyli.

Unfortunately, being much streightened for time when I opened the body, I was obliged to take out the parts for a more careful examination at home, which deprived me of the opportunity of ascertaining the above circumstances at the time I separated the parts, and consequently of inquiring how much further up this singular officiation extended, and in what state the duct might be at its entrance into the sub-clavian vein. The vena azygos, as well as the aorta, was perfectly found.

The vena cava was not so free from disease; for though it bore externally a natural appearance, when I laid it open from finding a singular feel within, I found that its cavity was above half filled with a firm inelastic substance:

this

this substance originated from its internal surface near the entrance of the emulgent vein, attached to it here and there by small points, till about the projection of the sacrum, where the cavity of the vein was almost filled up with a continuation of the same substance.

The spleen, pancreas, and liver, were perfectly sound: the gall bladder very small, and quite empty; its ducts in a natural state.

The kidneys were much increased in their substance, externally more livid than usual, and seemingly in a state of inflammation. The ureter on the right side was much enlarged, and contained a considerable quantity of urine, which seemed retained there by the distension of the bladder. The left ureter was of its natural size and appearance. The coats of the bladder were considerably thickened, but preserving externally as well as internally its most healthy appearance.

It may be necessary here to remark, that as the bladder could not expand itself laterally, it was extended upwards in an oblong form, not unlike that of a calf's, but did not appear capable of containing more than a quart.

The tumor which occupied the right iliac region, extended itself irregularly in all directions, and appeared outwardly to have destroyed or brought on an absorption

of

of a principal part of the os innominatum, so far as this could be ascertained by thrusting a probe into it in different directions.

The manner in which a portion of this tumor pressed on the neck of the bladder readily accounts for the difficulty of passing the catheter, though a bougie easily slipped in, and gives us a reason why the patient was unable to empty his bladder for so long a time before his death.

The degree of injury the os innominatum has sustained cannot yet be certified, the tumor not being sufficiently reduced by maceration. Where the bone is cleared from the surrounding soft parts, it appears to have suffered a great loss of substance, and, as the tumor dissolves, a large quantity of bony matter now deprived of its connecting medium is continually subsiding to the bottom of the vessel in which the tumor is macerating.

The preparation of the thoracic duct was at first put up in spirits to preserve its original appearance, and in this state I brought it with me to London. Upon shewing it here to several anatomical gentlemen, they were in doubt whether there might not be yet remaining some small cavity in the duct, and were therefore desirous I should take the preparation out of the spirits to be examined more accurately. This I readily complied with,
and

and it was accordingly examined very circumstantially by Dr. HUNTER, Mr. WATSON, Mr. J. HUNTER, and Mr. CRUIKSHANKS, who honoured me with a visit for that purpose.

The appearances which these gentlemen particularly noticed were, that the duct was completely filled up, excepting at the lower bulbous part, commonly called the receptaculum chyli, where, indeed, there was room enough for air to pass between the coat of the duct and the adventitious substance within it; so that the receptacle, which before appeared flat, upon throwing in air became rounded and fully distended: but this air was totally confined to the receptacle, and could not be forced up the duct in the smallest degree. The receptacle was then slit open, and an attempt made to pass a bristle up the duct, but this was found impossible.

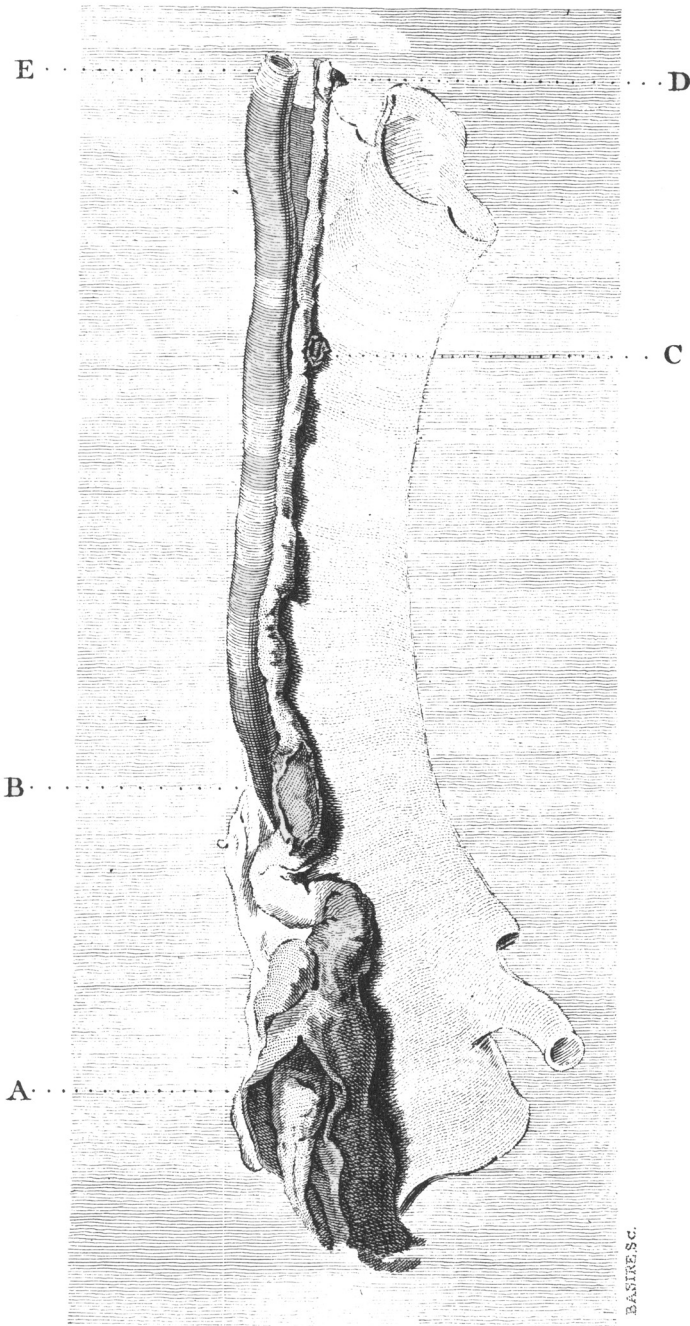
Mr. CRUIKSHANKS afterwards endeavoured to force mercury up the duct, but not the smallest particle would pass.

From these different examinations we were all thoroughly convinced, that the receptaculum chyli was not so completely filled up but that it might receive a small quantity of fluid, yet the duct itself was totally impervious, without a possibility of admitting any.

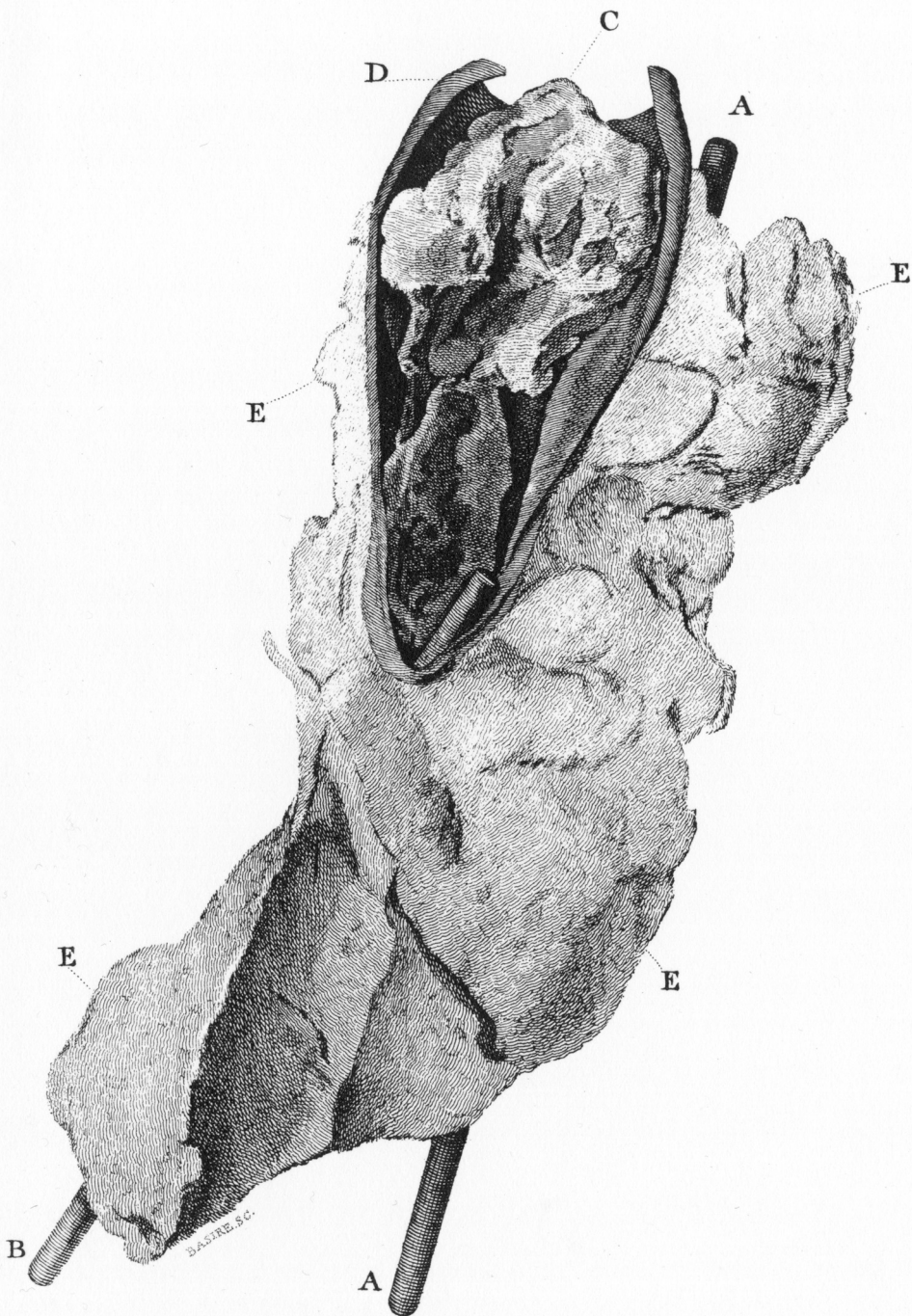
The coats of the duct did not appear to have undergone any morbid change: for in some places where the substance it contained was not so strongly attached but that the coat would admit of being raised from it, they were found in a perfect natural condition. At other places, where the attachment was inseparable, there was a greater appearance of ossification externally; but this we were convinced arose merely from the thinness of the coats in that part, where the receptaculum chyli was laid open, the substance within it appeared of a membranous nature very similar to that found in the vena cava of this same subject, but more laminated. We presumed, that the same kind of membrane had been continued through the whole of the duct, but was now become pretty completely ossified in all that portion of the duct which we were in possession of.

A small body, resembling a lymphatic gland on the side of the upper part of the duct, was opened by Mr. J. HUNTER, who found the same ossific disposition in this little body, as we before noticed in the duct itself.

We next examined the substance that partly filled up the vena cava. It was in length about four inches; at the upper end, broad and conical; at the lower, much narrower and rather rounded. Its surface appeared irregular and granulated with small bony particles. It



A. The Receptaculum Chyli laid open to shew the ligamentous Substance within it.
B. An Opening into the Thoracic Duct to shew the manner in which it was block'd up.
C. The little lymphatic Gland containing a similar Substance to that in the Receptac. Chyli.
D. The Coats of the Duct seperated from the boney Matter with which it was completely fill'd.
E. Vena Azygos.



A. A Bougie in the descending Aorta, the lower point having pass'd into the left Iliac.
B. A red Bougie in the lower part of the Vena Cava.
C. The Ligamentous Substance filling up the Vena Cava. D.
E. The bony Matter surrounding the Aorta & Vena Cava.

appeared flattened, perhaps from the pressure of the blood constantly moving over it; for having made a small opening with a lancet into the narrow part of this substance, we could pass a probe very readily both upwards and downwards, so as to convince us, it was really hollow all the way. Upon introducing a blow-pipe, the upper part was expanded into a large *cul de sac*, and the lower distended pretty much like a large vessel. The appearance of this man during his illness, as well as at the time of his death, was exactly similar to what I had frequently observed in patients who had lingered under, and been destroyed by, slow inflammations of the viscera. His complaints in the abdomen only indicated a diseased bladder, and, for that reason, I opened him: for he was not even so much emaciated as we often find patients under that disease.

